The role of impella in the pre-procedural management of post-infarct ventricular septal defect: a systematic review

Marco Gemelli[1,2], Daniele Ronco[1,3], Michele Di Mauro[1], Paolo Meani[4,5], Mariusz Kowalewski[4,6], Gary Schwartz[7], Rakesh C. Arora[8], Glenn Whitman[9], Evgenij Potapov[10], Dominik Wiedemann[11], Daniel Zimpfer[11], Milan Milojevic[12,13], Gaik Nersesian[10], Leonardo Salazar[14], Sandro Gelsomino[1], Gino Gerosa[2*], Roberto Lorusso[1*]

[1] Cardio-Thoracic Surgery Department, Maastricht University Medical Centre (MUMC), Maastricht, the Netherlands

[2] Cardiac Surgery Unit, Department of Cardiac, Thoracic, Vascular and Public Health Sciences, University of Padova, Italy

[3] Cardiac Surgery Unit, ASST Grande Ospedale Metropolitano Niguarda, Milan, Italy

[4] Thoracic Research Centre, Collegium Medicum Nicolaus Copernicus University, Innovative Medical Forum, Bydgoszcz, Poland

[5] Department of Cardiothoracic and Vascular Anesthesia and Intensive Care Unit, IRCCS Policlinico, San Donato Milanese, Milan, Italy

[6] Department of Cardiac Surgery and Transplantology, National Medical Institute of the Ministry of Interior and Administration, 02-507 Warsaw, Poland

[7] Department of Thoracic Surgery, Baylor University Medical Center, Dallas, Texas, USA

[8] Division of Cardiac Surgery, Department of Surgery, Harrington Heart and Vascular Institute, University Hospitals, Case Western Reserve University, Cleveland, Ohio

[9] Division of Cardiac Surgery, Johns Hopkins University, Baltimore, Maryland

[10] Department of Cardiothoracic and Vascular Surgery, Deutsches Herzzentrum der Charité (DHZC), Berlin, Germany

[11] Department of Cardiac Surgery, Medical University of Vienna, Vienna, Austria

[12] Department of Cardiac Surgery and Cardiovascular Research, Dedinje Cardiovascular Institute, Belgrade, Serbia

[13] Department of Cardiothoracic Surgery, Erasmus MC, Rotterdam, Netherlands

[14] Department of Cardiology, Fundación Cardiovascular de Colombia, Bucaramanga, Colombia

[*]: co-senior authors.

Corresponding Author:

Marco Gemelli, MD

Cardio-Thoracic Surgery Department

Maastricht University Medical Centre (MUMC)

Maastricht, the Netherlands

E-mail: marco.gemelli.01@gmail.com

Glossary of Abbreviations:

AMI: acute myocardial infarction

CABG: coronary artery bypass grafting

ECMO: extracorporeal membrane oxygenation

IABP: intra-aortic balloon pump

LV: left ventricle

LVAD: left ventricular assist device

MCS: mechanical circulatory support

PCI: percutaneous coronary intervention

RV: right ventricle

VSD: ventricular septal defect

Abstract:

Objectives: Post-infarct ventricular septal defect is a rare but devastating complication. Delayed treatment offers better outcomes than emergency surgery, but, when acute cardiogenic shock or unstable hemodynamics occur, temporary mechanical circulatory support may be needed to stabilize patients until treatment. The aim of our systematic review was to assess the outcomes of using Impella in this setting.

Methods: A systematic search was performed in Medline and EMBASE databases and all the papers about the use of Impella in this setting were assessed. The study followed the PRISMA criteria.

Results: A total of 20 papers encompassing 68 patients with an Impella implanted after the diagnosis of post-infarct ventricular septal defect and before its treatment were included. More than 95% were in cardiogenic shock when Impella was implanted, and half had another mechanical circulatory support device. Most of the patients (62%) had a posterior defect and 72% underwent surgical or percutaneous repair. Total in-hospital mortality was 47% and a total of 29 Impella-related complications were observed. Patients with surgical Impella had a numerically lower in-hospital mortality (35% vs. 58%) and a lower rate of complications compared to percutaneous device.

Conclusion: Impella represents an effective device for diminishing low output syndrome, improving peripheral perfusion, and unloading both the ventricles. It can be used as an upgrade from another mechanical circulatory support or as an addition to extra-corporeal membrane oxygenation to provide adequate left ventricular or biventricular support. Despite this, Impella-related complications can occur after its implantation and must be considered.

Keywords: VSD; MCS; Impella; Cardiogenic shock; ECMO; AMI

Introduction

Post-acute myocardial infarction ventricular septal defect (AMI-VSD) is a communication between the left and the right ventricles which occurs after trans-mural necrosis and rupture of a portion of the septum, often leading to life-threatening hemodynamic complications. Its incidence has significantly decreased after the introduction of percutaneous coronary revascularization strategies, and recent studies highlighted its very low prevalence, complicating only 0.2% of MIs.[1] Despite this rare occurrence, its clinical impact remains extremely high, with in-hospital mortality reaching 90% with conservative management and 20% to 60% when surgically managed.[1-10] Recent American College of Cardiology/American Heart Association (ACC/AHA) guidelines have recommended emergent surgery, even in stable patients.[11] On the other hand, the most recent European guidelines recommend, when possible, medical management and delayed surgical repair as the best approach.[12] An analysis of the STS database showed that the mortality of patients operated on in the first 7 days was higher than 50%, while it decreased to less than 20% if surgery was delayed after 7 days from diagnosis.[2] Furthermore, the recent CAUTION study, an international retrospective multi-center investigation, has shown that early surgery was independently associated with lower survival.[4] On the other hand, these findings are impacted both by clinical stabilization and improvement of tissue characteristics in patients with delayed surgery as well as selection bias during preoperative course.

It is well-known that delaying AMI-VSD treatment may provide more favorable structural features.[13] Indeed, the time required to develop a fibrotic reaction solidifying the necrotic myocardial tissue appears to give a more stable surface where to stich the patch or deployed a trans-defect percutaneous closure device, allowing for a more reliable repair and healing. Despite this, it must be recognized that only the healthier or less hemodynamically compromised patients survive until AMI-VSD repair when it is delayed. In contrast, the issue remains for the management of the unstable ones.[13]

As highlighted by the European guidelines, refractory cardiogenic shock and unresponsive right ventricle dysfunction are an indication for prompt surgery despite the known suboptimal results.[12] Recently, a growing body of literature has assessed the role of temporary mechanical circulatory support (tMCS) devices in patients with post-AMI-VSR and cardiogenic shock.[14-16] The rationale behind tMCS in this setting is to improve the patient's hemodynamic status, reducing the intra-ventricular shunt and low output syndrome and subsequent end-organ dysfunction. Currently, an intra-aortic balloon pump (IABP) has been the only first-line device recommended by European guidelines. [12] Still, its effectiveness is limited, particularly in patients with large left-to-right shunt, cardiogenic shock or/and biventricular dysfunction.[15]

The most frequently used tMCS modality in the cardiogenic shock settings is veno-arterial extra-corporeal membrane oxygenation (VA-ECMO), which can provide right ventricular (RV) unloading and circulatory support with systemic oxygenation. Despite these beneficial actions, it may significantly increase left ventricular (LV) afterload, which could preclude myocardial recovery due to the increase in left ventricular distention, often associated with pulmonary edema and an increased left-to-right ventricular shunt.[15] An IABP may be used with VA-ECMO to decrease the LV afterload, but a more effective method would be direct unloading with Impella in the so-called “ECMELLA” configuration. The Impella is a continuous flow intra-aortic microaxial flow pump which drains blood from the left ventricle and ejects it into the aorta. This is a pure temporary left ventricular assist device (tLVAD) that provides excellent LV unloading with significant improvement in peripheral perfusion. However, due to the high suction effect on the LV, the hemodynamic effects may reverse the shunt, leading to hypoxic aortic and systemic perfusion. [17, 18]

This study aimed to systematically review the literature regarding the use of Impella in the setting of post-AMI VSD and assess its indications, complications, and outcomes.

Materials and Methods

Ethical Statement

Our study was exempt from ethics approval as only data published by authors who had already obtained informed consent for previous studies were collected and synthesized. The present systematic review followed the Preferred Reporting Items for Systematic Reviews and Meta-Analyses (PRISMA) statement. [19]

Search Strategy, Study Selection and Data Extraction

A search strategy was designed to identify all the articles about the use of Impella in the setting of post-AMI VSR. The following online databases were searched on November 10th, 2023: Medline and EMBASE. The search strategy included the following terms: “ventricular septal defect”, “ventricular septal rupture”, “ventricular septal perforation”, “myocardial infarction”, “acute coronary syndrome”. Different search strategies were run, and we selected the one with the most results with the aim to limit the possibility of missing studies; its details are available in Supplementary Material 1. Two independent investigators (MG and DR) screened the retrieved articles, and a third investigator (RL) resolved any conflict for inclusion. Only articles reporting the use of the Impella device in the pre-operative setting of post-infarct VSR in adult patients (>18 years old) were screened. The reference lists of those articles selected were checked for further significant publications. Studies where Impella was positioned during or after the surgical or percutaneous treatment for the VSR were excluded from the analysis. Only publications in English were considered and abstracts not accompanied by peer-reviewed papers were excluded. Case reports, case series, observational studies, and registries were included. After full-text analysis, the following data were extracted from each article: general information about the study and patients' pre-operative, intra-operative and post-operative characteristics. Detailed data on the

characteristics of post-infarct VSR presentation and treatment and Impella implantation and outcomes were collected.

Statistical Analysis

After the extracting numerical data, raw numbers with percentages were used to represent categorical variables and range with the minimum and the maximum value for continuous variables. As no comparative studies were available and most included studies were case reports, we could not meta-analyze the data.

Results

Characteristics of the studies

A total of 6417 potentially relevant papers were identified through a systematic research strategy in two different databases and 1929 were removed after manual duplicate detection. Titles and abstracts of the remaining 4488 papers were screened for relevance and 4422 were excluded, not meeting the inclusion criteria. Of the 66 resulting papers, 65 were assessed through a full-text analysis for eligibility and 1 was not retrieved. Forty-five reports were excluded they as they were solely abstracts (n = 20) or addressed the wrong population (n = 14), the wrong type of article (n = 7), duplicates not found at the first analysis (n = 2), not in English (n = 1) and about patients already represented in other studies already included ("overlapping population") (n = 1). In the end, 20 studies were included in the review. The PRISMA study flow chart is represented in Supplementary Material 2.

Of the 20 selected papers, one was a retrospective analysis[20], six were case series[21-26], 12 were case reports[17, 18, 27-36] , and one was image-focused[37]. The majority (15, 75%) were published after 2020 and the most represented country was Japan with eight papers, followed by USA (6) and Italy (3). Delmas et al.[20] reported a European multicentric study involving 17 centers, while the remaining reports were single- or bi-institutional (Table 1). Ruiz Duque et al.[22] described a case series of four patients, but only three had the Impella positioned pre-operatively, and these were included in the analysis.

Characteristics of the population

A total of 68 patients had an Impella device positioned in the pre-procedural setting of a post-AMI VSD. The range of age went from a minimum of 45 to a maximum of 79 years, and 20 (29%) patients were women. More than 95% of the patients were in cardiogenic shock when Impella was positioned and the left ventricular ejection franction (LVEF) ranged

between 25 and 60%. The right coronary artery (RCA) was the culprit lesion in 35 (58%) patients, while the left anterior descending (LAD) artery in 24 (40%) (Table 2).

The VSD size ranged between 13 and 40 mm and the majority (39 patients, 62%) was located posteriorly. Forty-one patients (60%) had surgical VSD repair, 8 (12%) had percutaneous closure, and 2 (3%) had a heart transplantation. Seventeen patients (25%) had only medical treatment after Impella implantation. Primary percutaneous coronary intervention (PCI) was performed in 22 (32%) patients, while concomitant coronary artery bypass grafting (CABG) accompanied the surgical repair in 51% of patients (21/41 who had surgical repair) (Table 3).

Characteristics of Mechanical Circulatory Support

The time between the ischemic event and Impella implantation ranged between 1 and 17 days, while between Impella implantation and VSD treatment passed between 1 and 15 days. The total time of Impella support duration went from a minimum of 1 day to a maximum of 52 days and most patients had the Impella removed intraoperatively. For half of the patients, Impella was the first MCS positioned, while 34% had a IABP and 16% underwent ECMO implantation previously. Furthermore, biventricular support ("ECMELLA" or Impella + RVAD) was necessary in 16 (23.5%) patients. A percutaneous Impella (2.5 or CP) was positioned in 37 (56%) patients, and Impella CP (48% of the total) was the most frequent type of trans-valvular device, while 29 patients (44%) had a surgical device (Impella 5.0 or 5.5) (Table 4).

Post-Impella implantation outcomes

The total in-hospital mortality was 47% (32 patients), and 30% (15 patients) among patients who received closure of the VSD. All the 17 patients who did not reach the procedure died, while the 2 patients who had heart transplantation survived. There was a total of 29 Impella-

related complications and the most common complication was BARC ≥ 3 bleeding (16 patients, 24%), followed by hemolysis (6 patients, 9%), acute limb ischemia (4 patients, 6%), and device dysfunction (3 patients, 4%). Only two patients (3%) experienced an inversed (right-to-left) shunt, which was promptly reversed decreasing the Impella and increasing the ECMO flows (Table 5).

Post-Impella implantation outcomes by device

Compared to surgical device, patients with percutaneous Impella had a numerically higher rate of in-hospital mortality (58.3% vs. 35.5%), major bleeding (35.3% vs. 20%), acute limb ischemia (8.8% vs. 0%), hemolysis (14.7% vs. 5%) and CVA (11.8% vs. 5%). Furthermore, the Impella support time for percutaneous devices ranged between 1 and 9 days, while for surgical device between 9 and 52 days (Table 6).

Discussion

This systematic review has reported the literature evidence on the use of Impella in the setting of pre-procedural surgical or percutaneous treatment of post-AMI VSD and how this tMCS device could improve patients' hemodynamic status before treatment. Rob et al., in a recent study on the use of VA-ECMO in this setting, reported a 30-day mortality of more than 70% for patients with post-AMI VSD and treated in cardiogenic shock.[14] In the CAUTION trial, Ronco et al. showed a short-term mortality of 58% for patients presenting in cardiac arrest or cardiogenic shock, but it is not reported if Impella was used in this population.[4] A similar result was also found in the analysis of the STS database by Arnaoutakis et al.[2] Considering that more than 95% of patients were in cardiogenic shock when Impella was positioned, in-hospital mortality of 48% can be considered a good result compared to the literature data of patients treated without or with other types of tMCS in the same compromised hemodynamic condition.

While most of the VSDs in the literature were reported as antero-apical, we have found that 58% had the RCA as the culprit vessel and, consequently, 62% had a posterior VSD.[4] Jeppson et al. found that posterior rupture is an independent risk factor for early mortality and Matteucci et al., in a recent meta-analysis, confirmed that odds of operative mortality were significantly increased in patients with posterior VSD.[3, 38] We have speculated that the finding of a more frequent posterior VSD location is related to patients usually more unstable than those with an anterior VSD and with more chance to require a tMCS device to improve the hemodynamic status.

Advantages and Disadvantages of Impella in patients with post-MI VSD

Since delayed surgery for post-AMI VSD accounts for better outcomes, the most important advantage of Impella is the ability to hemodynamically stabilize the patients and often avoid an emergency surgery in the first hours or a few days. La Torre et al.[26] reported a case

series of 5 patients with cardiogenic shock and posterior VSR at hospital admission: in these patients Impella was used to improve the hemodynamic status and delay surgery until scar tissue forms around the defect, allowing a better and secure surgical repair. They found that, after Impella positioning, patients improved significantly in terms of hemodynamic and lab data: Qp/Qs, systolic pulmonary artery pressure (sPAP), pulmonary capillary wedge pressure (PCWP), central venous pressure (CVP), venous oxygen saturation (SvO_2), serum creatinine, glutamic-oxaloacetic transaminase (GOT), glutamic-pyruvic transaminase (GPT), total bilirubin, international normalized ratio (INR), and creatine-kinase MB (CK-MB) were significantly lower, while the cardiac index significantly improved.

Therefore, Impella improves the hemodynamic status of patients, providing better perfusion of peripheral organs and unloading of left ventricle. Furthermore, reducing the left-to-right shunt, it also provides right ventricle unloading: Via et al.[25] presented two patients with post-AMI VSD and severe RV dysfunction where, after Impella implantation, echocardiography showed rapid RV and inferior vena cava size reduction and effective RV unloading. In case of severe biventricular dysfunction, which does not improve after Impella positioning, VA-ECMO can be used to unload the RV further. ECMELLA is, in these circumstances, the best tMCS mode to both unload the left ventricle reducing the low output syndrome and decreasing preload and volume work in the RV.[17]

However, one of the peculiar characteristics of the use of tMCS in patients with VSD is the potential impact on the shunt direction. Through its suction-based action, Impella can significantly reduce the left-to-right shunt, reducing the RV overload. On the other hand, the risk is to invert the flow of the shunt creating a right-to-left shunt with a high risk of systemic deoxygenation and thromboembolic episodes should be taken into consideration.[15] Frequent echocardiographic guidance and adaptation of Impella-related LV unloading are needed to set the Impella on the higher flow to reduce the left-to-right shunt but concomitantly avoid the reversion of the shunt.[17, 18, 37] Sato et al. presented an

interesting case image where the authors showed the direction of the shunt was convertible: inversion of the flow was reached at P6 and systemic deoxygenation at P8, while at P4, hemodynamics was acceptable without a right-to-left shunt.[37] When VA-ECMO and Impella are both in place, device-related hemodynamic actions have to be carefully adjusted in order to avoid right-to-left shunting. Hiraoka et al.[18] showed a case where a right-to-left shunt occurred in a post-AMI VSD patient on ECMELLA: increasing the VA-ECMO flow and decreasing the Impella power, the shunt flow changed from right-to-left to left-to-right, and both oxygenation level and cardiac function improved.

Finally, Impella was shown to be very effective in reducing regurgitation in patients with concomitant ischemic mitral valve insufficiency.[26, 36] Also, heart transplantation and durable LVAD implantation have been described in patients with VSD unfeasible for repair and bridged with Impella to such advanced heart failure treatments.[28, 31]

The time between Impella implantation and VSD surgical or percutaneous treatment was various and ranged from a minimum of 1 day to 2 weeks; this time allowed patients to recover from the acute low output syndrome and to start the scarring process in the infarcted area. After a week, the initial acute inflammatory phase is replaced by the fibrotic phase. During this period, which last several weeks until tissue remodelling is complete, acute inflammation agents and edema reduced, while myofibroblast number increased and collagen accumulated.[39] According to literature, we speculated that the longer you wait for the correction of the defect, the better tissue you could find. As it is highlighted in Tab. 6, surgical Impella devices allowed a longer circulatory support than percutaneous one and this could have improved the quality of tissue found at the repair leading to a lower in-hospital mortality (35% vs. 58%). The smaller rate of Impella-related complication following implantation of surgical devices could be the reason why a longer circulatory support was possible with those.

Proposal of an algorithm for MCS in post-MI VSD

The IABP is indicated as a first-line MCS device according to the European guidelines and its use can be considered as the first step in stable patients without significant low output syndrome, a small left-to-right shunt and absence of marked RV dilatation or hemodynamic compromise.[12] If, despite the optimal medical management and the IABP, the hemodynamic status continues to deteriorate upgrading with a more advanced MCS could become necessary. While in patients with severe RV o biventricular dysfunction, VA-ECMO is considered the gold standard, in the setting of an isolated LV dysfunction the Impella could be implanted as the first choice. Compared to the more commonly used IABP, Impella provides greater hemodynamic support and a significantly higher reduction of the left-to-right shunt with a concomitant unloading of both ventricles through the VSD. Therefore, it could guarantee sufficient support in patients with isolated LV failure and mild RV dysfunction, but its suction needs to be carefully evaluated to avoid shunt inversion (Right-to-Left) and, consequently, the risk of debris embolization. Finally, Impella can also be added to VA-ECMO in a configuration called "ECMELLA". This setting is useful, in patients on VA-ECMO, when a severe distension of the LV and/or a significant enlargement of the Left-to-Right shunt occur. Adding a VA-ECMO to Impella provides full cardio-circulatory support and biventricular unloading. After surviving the initial insult, the patient in ECMELLA could be weaned from ECMO. Impella could be a sufficient cardiocirculatory support until tissue remodelling is completed and surgical treatment is due. This could lead to a decrease in ECMO-related complications. A proposal algorithm is represented in Figure 1.

Potential Limitations or Complications of Impella in Post-AMI VSD

Potential drawbacks or complications occurring with the use of Impella in post-AMI VSD may include, besides the above-described inversion of the left-to-right to right-to-left shunt with systemic blood desaturation in the most powerful pumping mode (at P8 or P9),

embolism generated by septal debris sucked in the pump from the necrotic VSD edges, direct dislocation of the trans-aortic pump in the VSD, and the more notorious adverse events like pump dislodgement in the aorta or towards the sub-mitral apparatus.[40-42] It is therefore critical that systemic saturation is constantly monitored with Impella at P6 or P7, avoiding maximal pump speed like P8 or P9. Also, concomitant V-A ECMO in case of refractory RV dilatation and/or desaturation needs to be applied with a moderated Impella pump suction (from P5 to P7) since pulmonary congestion may still occur or concomitant lung dysfunction with inadequate gas exchange.

Major bleeding, acute limb ischemia, hemolysis and CVA are all typical complications of the Impella device and needs to be considered after its implantation; despite this, surgical devices showed a lower rate of adverse events compared with their percutaneous alternatives, despite having a longer time of support. Considering this, the use of surgical Impella, and in particular the “new” 5.5, could decrease the rate of device-related complications and should be favored in this setting.

Limitations of the review

To our knowledge this is the first systematic review which analyzes the results of the use of Impella in the setting of post-AMI VSD. Still, its results must be interpreted in the context of the study's limitations. Firstly, most of the studies were case reports and case series, which did not allow direct comparison with a control group and a statistical analysis of the data. Also, no study where Impella was compared to other tMCS devices was found, and a meta-analysis comparing different approaches was not feasible. Finally, since most studies are case reports or case series, information bias, selection bias and publication bias could have influenced results. Successful cases could have been more frequently reported than unsuccessful ones, creating a potentially serious bias in the description and data interpretation of postoperative outcomes in this setting.

Conclusion

If hemodynamic instability persists despite optimal medical therapy, Impella could represent a valuable and useful tMCS in the setting of post-AMI VSD. This strategy may not only reduce the low output syndrome improving the peripheral perfusion, but also unload the left ventricle and reduce the left-to-tight shunt. If severe biventricular failure, or RV dilatation despite Impella-based shunt reduction, or respiratory failure due to lung dysfunction, occurs, ECMELLA could be a valuable option, providing a total circulatory support and biventricular unloading with concomitantly improved gas exchange. On the other hand, possible complications of the device need to be considered before its implantation. More studies are needed to evaluate and compare the different tMCS approaches in patients with post-MI VSD and cardiogenic shock.

Funding statement: no funding.

Conflict of interest statement: all authors have no conflict of interests related to this manuscript.

Data availability statement: all the data are available from the corresponding author on request.

Author contribution statement:

Marco Gemelli: Conceptualization; Data curation; Formal analysis; Investigation; Methodology; Project administration; Validation; Visualization; Writing—original draft; Writing—review & editing. **Daniele Ronco:** Conceptualization; Data curation; Formal analysis; Investigation; Methodology; Project administration; Validation; Visualization; Writing—review & editing. **Michele Di Mauro:** Supervision; Validation; Writing—review & editing. **Paolo Meani:** Supervision; Validation; Writing—review & editing. **Mariusz Kowalewski:** Supervision; Validation; Writing—review & editing. **Gary Schwartz:** Supervision; Validation; Writing—review & editing. **Rakesh C. Arora:** Supervision; Validation; Writing—review & editing. **Glenn Whitman:** Supervision; Validation; Writing—review & editing. **Evgenij Potapov:** Supervision; Validation; Writing—review & editing. **Dominik Wiedemann:** Supervision; Validation; Writing—review & editing. **Daniel Zimpfer:** Supervision; Validation; Writing—review & editing. **Milan Milojevic:** Supervision; Validation; Writing—review & editing. **Gaik Nersesian:** Supervision; Validation; Writing—review & editing. **Leonardo Salazar:** Supervision; Validation; Writing—review & editing. **Sandro Gelsomino:** Supervision; Validation; Writing—review & editing. **Gino Gerosa:** Supervision; Validation; Writing—review & editing. **Roberto Lorusso:** Funding acquisition; Investigation; Project administration; Supervision; Writing—review & editing.

Figures

Graphical Abstract. Trans-Aortic Micro-Axial Flow Pump in Post-AMI VSD: A Systematic Review: a representation of the main findings of our study.

Figure 1. Proposal algorithm for MCS in post-MI VSD. *AMI: acute myocardial infarction. IABP: intra-aortic balloon pump. LV: left ventricle. VA-ECMO: veno-arterial extracorporeal membrane oxygenation. RV: right ventricle. VSD: ventricular septal defect.*

Tables

Table 1. Characteristics of the studies. ECMO: extracorporeal membrane oxygenation. RVAD: right ventricular assist device.

	Year	Type of pubblication	Journal	Country	Center(s)	N° of patients	N° of patients with Impella + ECMO/RVAD
Patanè 2009	2009	Case Report	International Journal of Cardiology	Italy	1	1	0
La Torre 2011	2011	Case Series	Texas Heart Institute Journal	Italy	1	5	0
Ibebuogu 2016	2016	Case Report	BMJ Case Reports	USA	1	1	0
Ancona 2017	2017	Case Report	Cardiovascular Interventions and Therapies	Italy	1	1	0
Iida 2019	2019	Case Report	Artificial Organs	Japan	1	1	0
Maeda 2020	2020	Case Report	Artificial Organs	Japan	1	1	1
Nakamura 2020	2020	Case Report	Artificial Organs	Japan	1	1	0
Via 2020	2020	Case Series	ESC Heart Failure	Switzerland	1	2	0
Cohen 2021	2021	Case Report	Annals of Thoracic Surgery	USA	1	1	0
Hiraoka 2021	2021	Case Report	EHJ - Case Reports	Japan	1	1	1
Kowatari 2021	2021	Case Report	Journal of Cardiac Surgery	Japan	1	1	1
Shimahara 2021	2021	Case Series	EHJ - Case Reports	Japan	1	1	1
Coyan 2022	2022	Case Report	Medicina	USA	1	1	0
Giudicatti 2022	2022	Case Report	Case Reports in Cardiology	Australia	1	1	0
Saito 2022	2022	Case Series	ICVTS	Japan	1	3	2
Sato 2022	2022	Image Focus	EHJ - Cardiovascular Imaging	Japan	1	1	0
Delmas 2023	2023	Original Article	ASAIO	Multi	17	28	9
Dimarakis 2023	2023	Case Report	Perfusion	USA	1	1	0
Jalli 2023	2023	Case Series	EHJ - Case Reports	USA	2	13	1
Ruiz Duque 2023	2023	Case Series	ASAIO	USA	1	3	0

Table 2. Pre-operative characteristics. LAD: left anterior descending. LVEF: left ventricular ejection fraction. RCA: right coronary artery.

Preoperative characteristics	Population	Range (min-max) or n (%)
Age, years	68	45 - 79
Female	68	20 (29.4)
Prior cardiac surgery	68	1 (1.5)
LVEF, %	40	25 - 60
Cardiogenic shock	66	63 (95.5)
Culpruit vessel:	60	
• **RCA**		35 (58)
• **LAD**		24 (40)
• **Circumflex**		1 (2)

Table 3. VSD characteristics. CABG: coronary artery bypass grafting. PCI: percutaneous coronary intervention. VSD: ventricular septal defect.

VSD Characteristics	Population	Range (min-max) or n (%)
Location:	63	
• Anterior		24 (38)
• Posterior		39 (62)
Size, mm	56	13 - 40
Treatment:	68	
• Surgical		41 (60.3)
• Percutaneous		8 (11.8)
• Heart Transplantation		2 (2.9)
• Medical treatment		17 (25)
Concomitant CABG	68	21 (30.8)
Primary PCI	68	22 (32.3)

Table 4. MCS characteristics. IABP: intra-aortic balloon pump. ECMO: extra-corporeal membrane oxygenator. MCS: mechanical circulatory support. MI: myocardial infarction. RVAD: right ventricular assist device.

MCS Characteristics	Population	Range (min-max) or n (%)
Pre-Impella MCS:	64	
• IABP		22 (34.3)
• ECMO		10 (15.6)
• None		32 (50)
Impella Device:	66	
• 2.5		5 (7.5)
• CP		32 (48.5)
• 5.0		22 (33.3)
• 5.5		7 (10.6)
Time from AMI to Impella, days	56	1 - 17
Time from Impella to VSD treatment, days	38	1 - 15
Total Impella support duration, days	64	1 - 52
Biventricular Support:	68	
• ECMELLA		15 (22.0)
• Impella + RVAD		1 (1.5)

Concomitant MCS:	68	24 (35.3)
• ECMO		16 (23.5)
• IABP		7 (10.3)
• RVAD		1 (1.5)

Table 5. Post-Impella implantation outcomes. AKI: acute kidney injury. CVA: cerebrovascular accident.

Post-Impella Outcomes	Population	N (%)
In-Hospital Mortality	68	32 (47.0)
Impella-related complications:	68	
• Inversed (right-to-left) shunt		2 (2.9)
• Major Bleeding		16 (23.5)
• Acute Limb Ischemia		4 (5.9)
• Device Disfunction		3 (4.4)
• Hemolysis		6 (8.8)
Other complications:	68	
• CVA		6 (8.8)
• AKI		15 (22)
• Infections		18 (26.5)

Table 6. Post-Impella implantation outcomes by devices. CVA: cerebrovascular accident.

Post-Impella Outcomes by Devices	**Percutaneous**	**Surgical**
	37 patients	*31 patients*
In-Hospital Mortality	21/36 (58.3%)	11/31 (35.5%)
Mean Impella support duration, days, Range (min-max)	1 - 9	9 - 52
Complications:		
• Inversed (right-to-left) shunt	2/34 (5.8%)	0/20
• Major Bleeding	12/34 (35.3%)	4/20 (20%)
• Acute Limb Ischemia	3/34 (8.8%)	0/20
• Hemolysis	5/34 (14.7%)	1/20 (5%)
• CVA	4/34 (11.8%)	1/20 (5%)

References:

[1] Elbadawi A, Elgendy IY, Mahmoud K, Barakat AF, Mentias A, Mohamed AH *et al. Temporal Trends and Outcomes of Mechanical Complications in Patients With Acute Myocardial Infarction*. JACC Cardiovasc Interv 2019;12:1825-36.

[2] Arnaoutakis GJ, Zhao Y, George TJ, Sciortino CM, McCarthy PM, Conte JV. *Surgical repair of ventricular septal defect after myocardial infarction: outcomes from the Society of Thoracic Surgeons National Database*. Ann Thorac Surg 2012;94:436-43; discussion 43-4.

[3] Matteucci M, Ronco D, Corazzari C, Fina D, Jiritano F, Meani P *et al. Surgical Repair of Postinfarction Ventricular Septal Rupture: Systematic Review and Meta-Analysis*. Ann Thorac Surg 2021;112:326-37.

[4] Ronco D, Matteucci M, Kowalewski M, De Bonis M, Formica F, Jiritano F *et al. Surgical Treatment of Postinfarction Ventricular Septal Rupture*. JAMA Netw Open 2021;4:e2128309.

[5] Giblett JP, Matetic A, Jenkins D, Ng CY, Venuraju S, MacCarthy T *et al. Post-infarction ventricular septal defect: percutaneous or surgical management in the UK national registry*. Eur Heart J 2022;43:5020-32.

[6] Crenshaw BS, Granger CB, Birnbaum Y, Pieper KS, Morris DC, Kleiman NS *et al. Risk factors, angiographic patterns, and outcomes in patients with ventricular septal defect complicating acute myocardial infarction. GUSTO-I (Global Utilization of Streptokinase and TPA for Occluded Coronary Arteries) Trial Investigators*. Circulation 2000;101:27-32.

[7] Menon V, Webb JG, Hillis LD, Sleeper LA, Abboud R, Dzavik V *et al. Outcome and profile of ventricular septal rupture with cardiogenic shock after myocardial infarction: a report from the SHOCK Trial Registry. SHould we emergently revascularize Occluded Coronaries in cardiogenic shocK?* J Am Coll Cardiol 2000;36:1110-6.

[8] Dimagli A, Guida G, Sinha S, Dixon L, Fudulu D, Gemelli M *et al. Surgical outcomes of post-infarct ventricular septal defect repair: Insights from the UK national adult cardiac surgery audit database*. J Card Surg 2022;37:843-52.

[9] Ronco D, Matteucci M, Ravaux JM, Kowalewski M, Massimi G, Torchio F *et al. Impact of COVID-19 on incidence and outcomes of post-infarction mechanical complications in Europe*. Interdiscip Cardiovasc Thorac Surg 2023;37.

[10] Pojar M, Harrer J, Omran N, Turek Z, Striteska J, Vojacek J. *Surgical treatment of postinfarction ventricular septal defect: risk factors and outcome analysis*. Interact Cardiovasc Thorac Surg 2018;26:41-46.

[11] O'Gara PT, Kushner FG, Ascheim DD, Casey DE, Chung MK, de Lemos JA *et al. 2013 ACCF/AHA guideline for the management of ST-elevation myocardial infarction: a report of the American College of Cardiology Foundation/American Heart Association Task Force on Practice Guidelines*. Circulation 2013;127:e362-425.

[12] Byrne RA, Rossello X, Coughlan JJ, Barbato E, Berry C, Chieffo A *et al. 2023 ESC Guidelines for the management of acute coronary syndromes*. Eur Heart J 2023;44:3720-826.

[13] Jones BM, Kapadia SR, Smedira NG, Robich M, Tuzcu EM, Menon V *et al. Ventricular septal rupture complicating acute myocardial infarction: a contemporary review*. Eur Heart J 2014;35:2060-8.

[14] Rob D, Špunda R, Lindner J, Rohn V, Kunstýř J, Balík M *et al. A rationale for early extracorporeal membrane oxygenation in patients with postinfarction ventricular septal rupture complicated by cardiogenic shock*. Eur J Heart Fail 2017;19 Suppl 2:97-103.

[15] Ronco D, Matteucci M, Ravaux JM, Marra S, Torchio F, Corazzari C *et al. Mechanical Circulatory Support as a Bridge to Definitive Treatment in Post-Infarction Ventricular Septal Rupture*. JACC Cardiovasc Interv 2021;14:1053-66.

[16] Møller JE, Engstrøm T, Jensen LO, Eiskjær H, Mangner N, Polzin A *et al. Microaxial Flow Pump or Standard Care in Infarct-Related Cardiogenic Shock*. N Engl J Med 2024;390:1382-93.

[17] Maeda K, Yoshioka I, Saiki Y. *Emergence of right to left shunt via postmyocardial infarction ventricular septal defect under Impella support*. Artif Organs 2021;45:316-17.

[18] Hiraoka A, Saku K, Nishikawa T, Sunagawa K. *A case report of unexpected right-to-left shunt under mechanical support for post-infarction ventricular septal defect: evaluation with haemodynamic simulator*. Eur Heart J Case Rep 2021;5:ytab209.

[19] Liberati A, Altman DG, Tetzlaff J, Mulrow C, Gøtzsche PC, Ioannidis JP *et al. The PRISMA statement for reporting systematic reviews and meta-analyses of studies that evaluate healthcare interventions: explanation and elaboration*. BMJ 2009;339:b2700.

[20] Delmas C, Barbosa H, David CH, Bouisset F, Piriou PG, Roubille F *et al. Impella for the Management of Ventricular Septal Defect Complicating Acute Myocardial Infarction: A European Multicenter Registry*. ASAIO J 2023;69:e491-e99.

[21] Jalli S, Spinelli KJ, Kirker EB, Venkataraman A, Abraham J. *Impella as a bridge-to-closure in post-infarction ventricular septal defect: a case series*. Eur Heart J Case Rep 2023;7:ytad500.

[22] Ruiz Duque E, Hohenwarter MR, Isom NR, Singhal AK. *Impella Support for Surgical Ventricular Septal Defect Repair*. ASAIO J 2023;69:e278-e83.

[23] Saito S, Shibasaki I, Matsuoka T, Niitsuma K, Hirota S, Kanno Y *et al. Impella support as a bridge to heart surgery in patients with cardiogenic shock*. Interact Cardiovasc Thorac Surg 2022;35.

[24] Shimahara Y, Fukushima S, Yajima S, Tadokoro N, Kakuta T, Asaumi Y *et al. Emergency sandwich patch repair*. Eur Heart J Case Rep 2021;5:ytab141.

[25] Via G, Buson S, Tavazzi G, Halasz G, Quagliana A, Moccetti M *et al. Early cardiac unloading with ImpellaCP in acute myocardial infarction with ventricular septal defect*. ESC Heart Fail 2020;7:708-13.

[26] La Torre MW, Centofanti P, Attisani M, Patanè F, Rinaldi M. *Posterior ventricular septal defect in presence of cardiogenic shock: early implantation of the impella recover LP 5.0 as a bridge to surgery*. Tex Heart Inst J 2011;38:42-9.

[27] Dimarakis I, Adcox M, Pal JD, Khorsandi M. *Impella 5.5 support before, during, and after surgical ventricular septal defect repair: A bridge continuum*. Perfusion 2023:2676591231182248.

[28] Giudicatti L, Silbert B, Xu XF, Putrino A, Lee F, Shah A *et al. Post-Myocardial Infarction Ventricular Septal Defect Successfully Treated with Impella as Bridge to Cardiac Transplantation*. Case Rep Cardiol 2022;2022:5690844.

[29] Coyan G, Anand N, Imran M, Gomez H, Ramanan R, Murray H *et al. ECMO and Impella Support Strategies as a Bridge to Surgical Repair of Post-Infarction Ventricular Septal Rupture*. Medicina (Kaunas) 2022;58.

[30] Kowatari R, Kondo N, Watanabe S, Daitoku K, Minakawa M. *Urgent repair of postinfarct ventricular septal rupture with ECPELLA support: A case report*. J Card Surg 2021;36:3933-35.

[31] Cohen JA, Montgomery RA, Zmaili MA, Rampersad P, Menon V, Tong MZ *et al. Post-Myocardial Infarction Ventricular Septal Rupture Bridged to Heartmate 3 with an Impella 5.5*. Ann Thorac Surg 2021;112:e161-e63.

[32] Nakamura M, Imamura T, Fukui T, Ueno Y, Ueno H, Yokoyama S *et al. Impella support as a bridge to scheduled surgical repair of ventricular septal rupture*. J Artif Organs 2020;23:278-82.

[33] Iida M, Uchiyama M, Shimokawa T. *A successful case of percutaneous left ventricular assist device "Impella" to postmyocardial infarction ventricular septal perforation in Japan*. Artif Organs 2019;43:806-07.

[34] Ancona MB, Regazzoli D, Mangieri A, Monaco F, De Bonis M, Latib A. *Post-infarct ventricular septal rupture: early Impella implantation to delay surgery and reduce surgical risk*. Cardiovasc Interv Ther 2017;32:381-85.

[35] Ibebuogu UN, Bolorunduro O, Hwang I. *Impella-assisted transcatheter closure of an acute postinfarction ventricular septal defect*. BMJ Case Rep 2016;2016.

[36] Patanè F, Grassi R, Zucchetti MC, Ceresa F, Amata AD, Zingarelli E *et al. The use of Impella Recover in the treatment of post-infarction ventricular septal defect: a new case report*. Int J Cardiol 2010;144:313-5.

[37] Sato S, Hiraoka A, Toki M, Chikazawa G, Yoshitaka H. *Right-to-left shunt depending on the support level of Impella for post-infarction ventricular septal defect*. Eur Heart J Cardiovasc Imaging 2022;23:e296.

[38] Jeppsson A, Liden H, Johnsson P, Hartford M, Rådegran K. *Surgical repair of post infarction ventricular septal defects: a national experience*. Eur J Cardiothorac Surg 2005;27:216-21.

[39] Richardson WJ, Clarke SA, Quinn TA, Holmes JW. *Physiological Implications of Myocardial Scar Structure*. Compr Physiol 2015;5:1877-909.

[40] Ancona MB, Montorfano M, Masiero G, Burzotta F, Briguori C, Pagnesi M *et al. Device-related complications after Impella mechanical circulatory support implantation: an IMP-IT observational multicentre registry substudy*. Eur Heart J Acute Cardiovasc Care 2021;10:999-1006.

[41] Toggweiler S, Jamshidi P, Erne P. *Functional mitral stenosis: a rare complication of the Impella assist device*. Eur J Echocardiogr 2008;9:412-3.

[42] Mutallimov M, Er F, Gassanov N. *Device fracture as a potential complication of a left ventricular microaxial pump catheter: a case report*. Eur Heart J Case Rep 2022;6:ytac335.

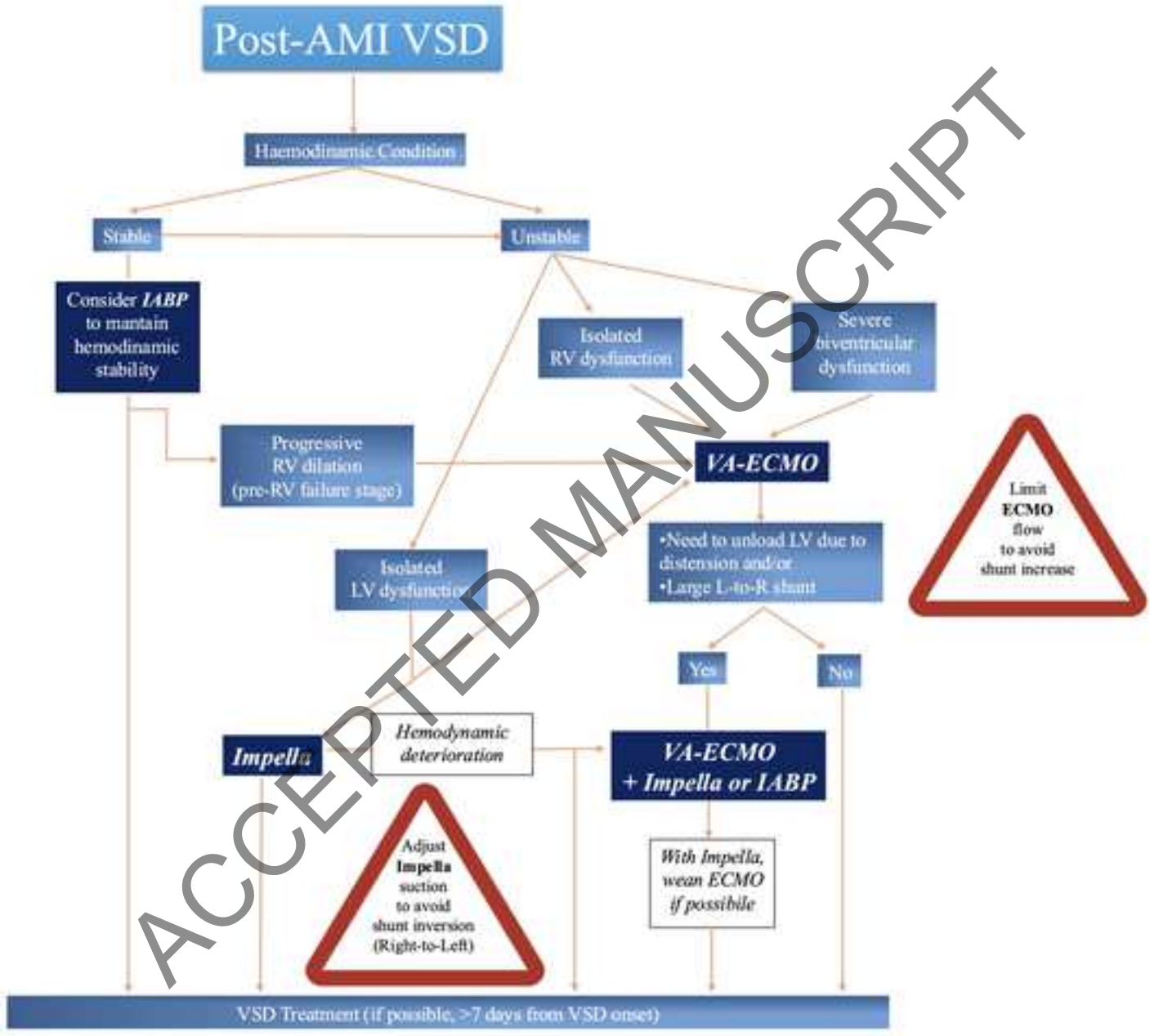

Trans-Aortic Micro-Axial Flow Pump in Post-AMI VSD: A Systematic Review

Summary

Systematic review of 68 patients who were supported with Impella before surgical repair od post-infarct VSD.

Use of an Impella improved:

- Low cardiac output syndrome and biventricular unloading

Patients with surgical devices had longer time on support but experienced improved survival and outcomes.

68 Patients (Case Report and Case Series)

Trans-Aortic Micro Axial Flow Pump Device:

Impella CP	48.5%
Impella 5.0	33.3%
Impella 5.5	10.6%
Impella 2.5	7.5%

Impella support duration

»Surgical» Impella	9-52 days
«Percutaneus» Impella	1-9 days

In-Hospital Mortality: 47.0%

»Surgical» Impella	35.5%
«Percutaneus» Impella	58.3%

Impella-related complication: 29

Legend: AMI: acute myocardial infarction. VSD: ventricular septal defect.